

# PEDIATRIC RETINAL DETACHMENTS REQUIRE DIFFERENT STRATEGIES



Each year, the Aspen Retinal Detachment Society (ARDS) hears from a select group of highly distinguished speakers. In several of our past meetings, we have made sure to reserve time on the podium to discuss pediatric retinal care.

ARDS leadership knows that most retina conferences give little attention to pediatric retina care. The reasons are obvious: Pediatric retina is a sub-subspecialty of eye care, and dedicating valuable podium time on an otherwise filled agenda to a discipline that only a small subset of attendees may practice could be unwise.

Still, we know our attendees. ARDS participants' hunger for learning deeply about a number of subjects is not limited to the topics that pertain most immediately to them and their practices. They're polymaths. They know that rounding out their retina education gives them a more holistic sense of the space. And hey, you never know when those pediatric retina pearls will come in handy.

Be sure to keep an eye on [MedConfs.com](http://MedConfs.com) for the latest updates about ARDS 2021 and our focus on an in-person meeting.

—Timothy G. Murray, MD, MBA

## BEST APPROACHES FOR PEDIATRIC RETINAL DETACHMENTS



### Presentation by Philip J. Ferrone, MD Summarized by Abdallah Mahrous, MD

At this year's ARDS meeting, Philip J. Ferrone, MD, provided a rundown of surgical considerations for pediatric retinal detachments (RDs). He emphasized the important point that the anatomy of pediatric eyes is different from the anatomy of adult eyes, and he discussed the best approaches to use in a variety of presentations. This article summarizes portions of his presentation.

#### HISTORY AND EXAMINATION TIPS

Dr. Ferrone reported that pediatric RDs have an incidence of 0.53 per 100,000, compared with an incidence of 12 per 100,000 in the adult population.<sup>1</sup> Tractional RDs are even less common in children. RDs are sometimes challenging to diagnose in children, and they can present late or with other signs such as strabismus.

History is important, even in older children—details such as a baby's birth weight, a history of prematurity, or a family history of eye disease or

RD, and trauma are important to document. Pediatric examinations can be made more challenging due to lack of cooperation, difficulty with drop administration, and poor dilation.

For babies less than 1 year old, examination can be made easier by having the patient lie on a parent's lap with the head by the knees and feet up to the parent's chest, while the parent helps stabilize the baby by holding his or her head. For uncooperative children up to 8 years of age, you can ask the parent to bear-hug the child while an assistant holds the head and the physician attempts to pry the eyelids open and examine. If this approach fails, examination under anesthesia is often necessary.

Stickler detachments are often complicated, with a redetachment rate of 45% due to proliferative vitreoretinopathy (PVR). By contrast, non-Stickler RDs often behave more like adult RDs with more promising results.

#### SURGICAL APPROACHES

The standard Alcon kit for 25-gauge vitrectomy can often be used for common pediatric RDs. Use of the special Alcon short 25-gauge instrumentation can be helpful in cases such as microphthalmic eyes, or eyes with persistent

fetal vasculature (PFV) with central retinal stalk lines, or peripheral retinal folds in retinopathy of prematurity (ROP). The short system has the advantage of providing a trocar with no cannula.

Pediatric eye anatomy varies from that of adults. The pars plana–pars plicata complex extends on average for 1.87 mm posterior to the limbus at 40 weeks; therefore, introducing the cannulas at 1 mm from the limbus is appropriate for a term baby. By 6 months, the pars plana–pars plicata complex extends for approximately 3 mm posterior to the limbus, so a trocar incision at 1.5 to 2.0 mm from the limbus is appropriate for that age.

The eye's anatomy continues to change with the child's growth. The axial length increases by approximately 1.5 mm during the first 12 weeks of life. The eye grows on average 2 mm over the first 2 years of life and then another 2 mm from 2 years to 5 years. Between 5 years and 15 years the eye typically grows another 3 mm. After 15 years of age, there is typically no significant growth.<sup>2</sup> It is important to take this progression into account when scleral buckle surgery is considered and when you are placing sclerotomy wounds.

## Eyetube Meeting Coverage at Aspen Retinal Detachment Society

Each year, the Society invites Eyetube to cover selected talks from the year's agenda.

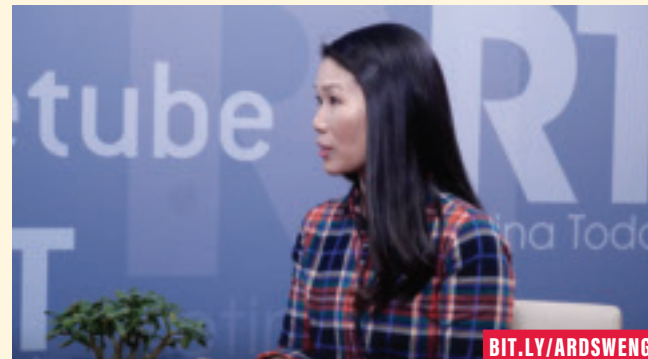### ARTIFICIAL INTELLIGENCE AND PEDIATRIC RETINA

R.V. Paul Chan, MD, discusses how applying AI to pediatric patients aids in diagnosing conditions such as plus disease by characterizing and monitoring disease activity.




### SUBRETINAL GENE THERAPY

Christina Weng, MD, MBA, gives insight into ongoing subretinal gene therapy pipeline candidates, specifically voretigene neparvovec for patients with a mutation of the *RPE65* gene.



### BEST APPROACHES FOR PEDIATRIC RD

Philip J. Ferrone, MD, discusses how to properly care for and diagnose pediatric patients. Dr. Ferrone discusses how fundus autofluorescence, OCT, and other in-office imaging modalities can be used to obtain the best and most accurate imaging results.



### NEUROPROTECTION FOR THE TREATMENT OF THE RETINA

Baruch Kuppermann, MD, PhD, discusses unmet needs in conditions such as retinal detachment, geographic atrophy, and dry AMD and what the right pathway may be for neural protection and enhancement.



Want to see the whole video collection? Head to [bit.ly/ARDS2020](https://bit.ly/ARDS2020).

### CASE-BY-CASE CONSIDERATIONS

Pediatric RDs should be approached on a case-by-case basis. Retinal dialysis should preferably be buckled using a low and broad approach, as opposed to a high and narrow one. Stickler detachments, as previously mentioned, are highly proliferative with high redetachment rates. Addressing

these RDs often requires time and patience. They might require multiple surgeries, with relaxing retinectomies and silicone oil.

Familial exudative vitreoretinopathy (FEVR) may present with a normal appearing fundus, but fluorescein angiography can reveal large areas of peripheral nonperfusion that can be

lasered. If not treated, these areas can lead to dense preretinal proliferation with high-ridged retinal folds. The folds must be carefully dissected, taking care not to create any retinal breaks, which would be very difficult to repair.

Mutations in *KIF11* can cause microcephaly, microphthalmia, and con-

*(Continued on page 15)*

(Figure, A). The macula showed a large retinal tear with an overlying hemorrhage (Figure, B).

The patient underwent fundus photography and emergency CT scan as per institution protocol. To our surprise, CT imaging revealed two separate IOFBs in the inferonasal aspect of the right eye (Figure, C).

The patient was scheduled for emergency 25-gauge pars plana vitrectomy and pars plana lensectomy with anterior capsulotomy. Posterior vitreous detachment nasally helped to avoid the extension of the macular tear. After vitrectomy, the larger of the two foreign bodies was removed through a clear corneal incision, while a thorough search with scleral indentation localized the second IOFB in the peripheral retina close to the ora (Figure, D). The second one was removed in a similar manner. Cryotherapy was applied to the peripheral break, followed by silicone oil tamponade. After silicone oil removal at 3 months postoperatively, visual acuity improved to counting fingers at 3 m with attached retina and scarring at the macula.

### DISCUSSION

The identification of an additional foreign body can be challenging when the level of suspicion is low, as can be the case when one IOFB is clinically visible. General consensus is lacking regarding the need for imaging in cases with visible IOFB.

In one interventional case series of 69 eyes with IOFBs, 17 eyes had no imaging when the IOFB was easily visualized.<sup>1</sup> The researchers also reported that two eyes had an additional IOFB identified on radiological evaluation. Thus, the authors recommended radiologic imaging even when an IOFB is clearly visible on clinical examination. A retrospective review of imaging techniques in IOFB cases demonstrated the superiority of CT scan over other methods.<sup>4</sup>

To the best of our knowledge, this is a unique report of two metallic IOFBs from a single entry site caused by a hammering accident. I speculate that the force of the IOFB's impact on the macula may have caused the IOFB to split in two inside the eye. This case highlights the need for suspicion and imaging for additional IOFBs in the event of high velocity projectile injuries, even when one IOFB is clinically evident. ■

1. Woodcock MG, Scott RA, Huntbach J, Kirby GR. Mass and shape as factors in intraocular foreign body injuries. *Ophthalmology*. 2006;113(12):2262-2269.  
 2. Roper-Hall MJ. Review of 555 cases of intra-ocular foreign body with special reference to prognosis. *Br J Ophthalmol*. 1954;38:65-99.  
 3. Perceval SP. A decade of intraocular foreign bodies. *Br J Ophthalmol*. 1972;56:454-461.  
 4. Nie S, Wang Z, Liu W, Liang X. Clinical application of X-ray, B-scan, and CT in the diagnosis of ocular foreign bodies. *Eye Sci*. 2013;28(1):11-4.

#### THOMAS CHERIAN, MS, FLVPEI

- Vitreoretinal Consultant, Little Flower Hospital and Research Center, Angamaly, Kerala, India
- Financial disclosure: None

#### REMYA MAREEN PAULOSE, MBBS, DNB, FLVPEI, FICO, FAICO

- Vitreoretinal Consultant, Little Flower Hospital and Research Center, Angamaly, Kerala, India
- remyapaulose@gmail.com
- Financial disclosure: None

(Continued from page 13)

genital retinal folds. Fluorescein studies may show peripheral nonperfusion as well. Retinal folds can sometimes have stalks that connect to the lens. The preferred surgical approach in these eyes is to use the short 25-gauge instruments, cutting the stalk anteriorly to free up the retina and letting it settle back down to a more normal anatomy, then approaching the rest of the retinal folds.

Optic pit RDs can sometimes self-resolve if given time; however, in cases that require surgery it is recommended to remove the vitreous stalk that goes right into the optic pit, followed by application of light intraoperative laser around the pit.

In Coats disease, the pathognomonic telangiectatic vessels are often accompanied by RDs. In these eyes, it is better to drain the subretinal fluid externally and apply extensive laser to the telangiectatic vessels; this might not provide ideal results but will preserve any vision possible.

Colobomas can present with very challenging RDs. Silicone oil is preferred in these eyes, but even with oil there are often redetachments due to the complexity of the retinal layers in the coloboma. Platelet-rich plasma can be helpful in these cases.

### CONCLUSION

Pediatric RDs are different from RDs in adults. Children's eyes have a different anatomy that requires modification of surgical approaches. With the correct approach and patience, excellent visual and anatomic results are still possible. ■

1. Nuzzi R, Lavia C, Spinetta R. Paediatric retinal detachment: a review. *Int J Ophthalmol*. 2017;10(10):1592-1603.

2. Maldonado RS, Izatt JA, Sarin N, et al. Optimizing hand-held spectral domain optical coherence tomography imaging for neonates, infants, and children. *Invest Ophthalmol Vis Sci*. 2010;51(5):2678-85.

#### CORRESPONDING AUTHOR ABDALLAH MAHROUS, MD

- Vitreo-Retinal Surgery Fellow, Weill Cornell Medicine, New York
- amahrus89@gmail.com
- Financial disclosure: None

#### PHILIP J. FERRONE, MD

- Retinal Surgeon, Long Island Vitreoretinal Consultants, Great Neck, New York
- Financial disclosure: None acknowledged